

What's New with Shoulder Care in Orthopedics

Benjamin W. Sears, MD
Western Orthopaedics
Denver, Colorado




Conflict of Interest Disclosure

•I have a financial interest / affiliation with these commercial entities

Consultant and Royalties – United Orthopaedic Corporation
Research funding – Arthrex, Inc.
Research funding – Wright






My Profile



- Practice in Denver, CO
– Western Orthopaedics
- From Aurora
- Residency at Loyola Chicago
- Fellowship at Rothman in Philadelphia
- Travelling fellowships in elbow surgery at Mayo and Western Ontario

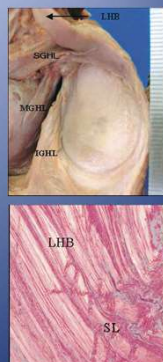
Overview

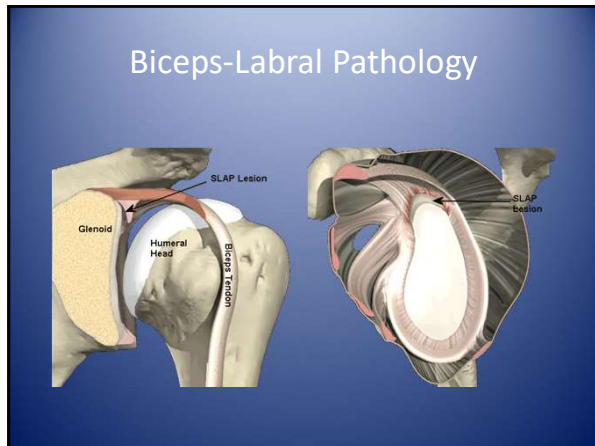
Overview

- What's new
 1. Labral pathology
 - Instability
 - Biceps-labral complex pathology (SLAP tears)
 2. Rotator cuff disease
 3. Shoulder arthritis
 4. Proximal humerus fractures

Biceps-Labral Pathology

- Superior labrum
 - Labrum: comprised of fibrocartilaginous tissue with sparse elastin fibers
 - Biceps fibers extend into posterior labrum
 - 40-60% biceps originates at supraglenoid tubercle





Biceps-labral Pathology

- **Typical Patients:**
 - Overhead athletes
 - Laborers
 - Weight lifters
 - Traumatic pull on the arm

Biceps-Labral Complex Pathology

- **Physical Examination**
 - Sandrey, J Athl Training 2013
 - Metaanalysis
 - No clinical tests helped rule in or out SLAP tear

Biceps-Labral Complex Pathology

- Exam

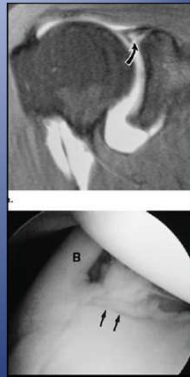
- San



Active Compression Test

Imaging

- MRI, Bencardino (2000)
 - Correlated MRI findings with arthroscopic findings prospectively in 159 patients
 - MRI arthrogram
 - Sensitivity 89%
 - Specificity 91%
 - Accuracy 90%



Treatment

- Non-operative management remains first line
 - Focused physical therapy x 6 weeks
 - Federiow et al. 2013: 66% professional baseball players returned to sport after focused therapy
 - Corticosteroid injection into glenohumeral articulation
 - PRP and stem cell injections
 - Still not great literature

Results of Non-operative Treatment

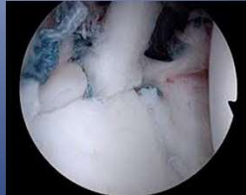
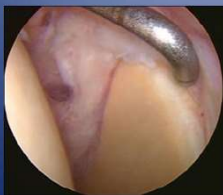- Edwards et al., AJSM 2010
 - Avg. 34 y.o, FU=3 years, 50 patients with diagnosed SLAP tear, 50% successfully treated non-operatively
 - Improved VAS, quality of life, ASES scores
 - Return to sport comparable to operatively treated group

Results of Non-operative Treatment

- Edwards et al., AJSM 2010
 - Avg. 34 y.o, FU=3 years, 50 patients with diagnosed SLAP tear, 50% successfully treated non-operatively
 - Improved VAS, quality of life, ASES scores
 - Return to sport comparable to operatively treated group
 - Conclusion - trial of non-operative treatment should be considered
 - NSAIDs, periscapular strengthening/stabilization, posterior capsular stretch

Treatment

- Surgical treatment
 - 83% patients found to have good-to-excellent results with surgery
- Primary repair



Biceps Tenodesis for SLAP tears

- Erickson et al., AJSM 2014
 - Systemic review of literature
 - Significantly higher failure rates of SLAP repair in patients > 40 yo
 - Decreased patient satisfaction
 - Postoperative stiffness and need for reoperation

Biceps Tenodesis for SLAP tears

- Erickson et al., AJSM 2014
 - Systemic review of literature
 - Significantly higher failure rates of SLAP repair in patients > 40 yo
 - Decreased patient satisfaction
 - Postoperative stiffness and need for reoperation
 - Workers' compensation status also an independent risk factors for increased surgical complications

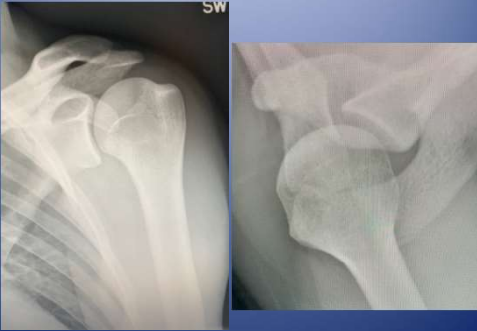Biceps Tenodesis for SLAP tears

- Erickson et al., AJSM 2014
 - Systemic review of literature
 - Significantly higher failure rates of SLAP repair in patients > 40 yo
 - Decreased patient satisfaction
 - Postoperative stiffness and need for reoperation
 - Workers' compensation status also an independent risk factors for increased surgical complications
 - **Conclusion-** Biceps tenotomy and tenodesis are reliable alternatives to SLAP repair in these populations

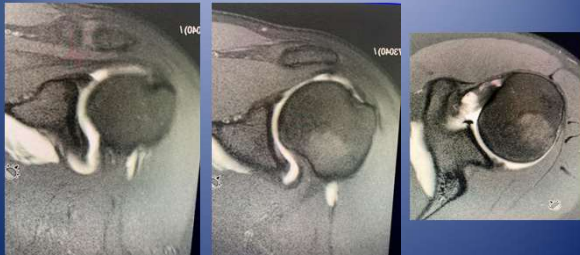
Case - RM

- 19 yo left handed collegiate pitcher
- Felt a pop and pain while pitching 6 months ago
- Complains of pain, diminished control and velocity

RM



RM



MR arthrogram read: questionable superior/posterior labral pathology

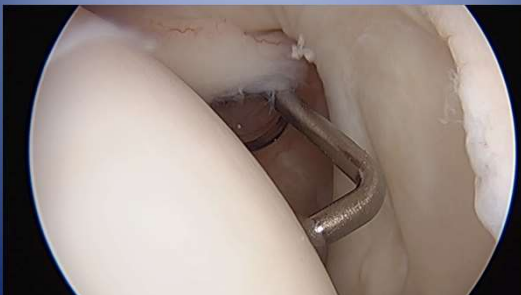RM

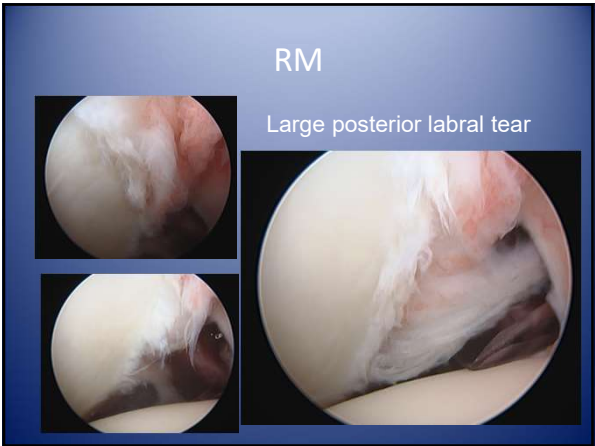
- Start with conservative management:
 - 3 months of complete throwing rest
 - Steroid injection with 50% relief for 2 months
 - Physical therapy with continued pain

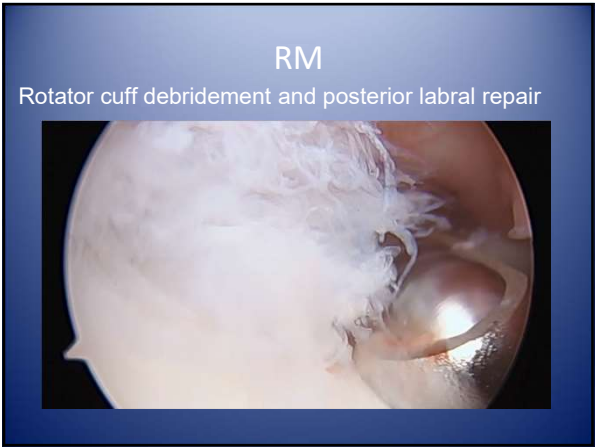RM

- Start with conservative management:
 - 3 months of complete throwing rest
 - Steroid injection with 50% relief for 2 months
 - Physical therapy with continued pain
- He is unable to continue pitching:
 - Now what?

RM









1 year postop

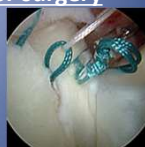

Glenohumeral Instability

- **Patients with instability**
 - Typically traumatic
 - Anterior dislocations most common
 - Watch out for patients who are naturally ligamentously lax
 - Age matters
 - Reoccurrence much more common in younger active patients
 - Associated rotator cuff tears more common in older patients

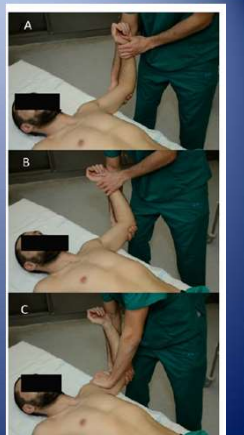
Traumatic Glenohumeral Instability

- **Incidence of recurrence and need for surgery**
 - Hovelius et al., JBJS 2008
 - 229 shoulders under 40 yo
 - 57% recurrence
 - 27% underwent surgical treatment
 - Sachs et al., JBJS 2007
 - 55% recurrence
 - 32% underwent surgical treatment



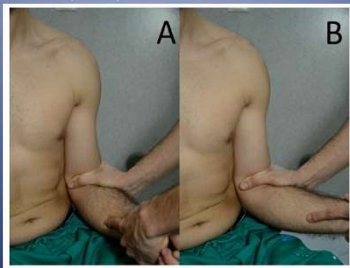
Examination Shoulder Instability

- Apprehension test and Relocation test
 - Anterior instability
 - 53% sensitivity
 - 98% specificity



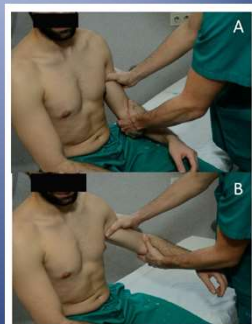
Examination Shoulder Instability

- Sulcus Sign
 - Ligamentously lax patients: inferior instability



Examination Shoulder Instability

- Kim test
 - Posterior-inferior labral tears
 - 97% sensitivity

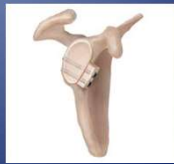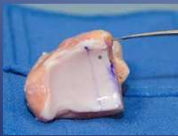


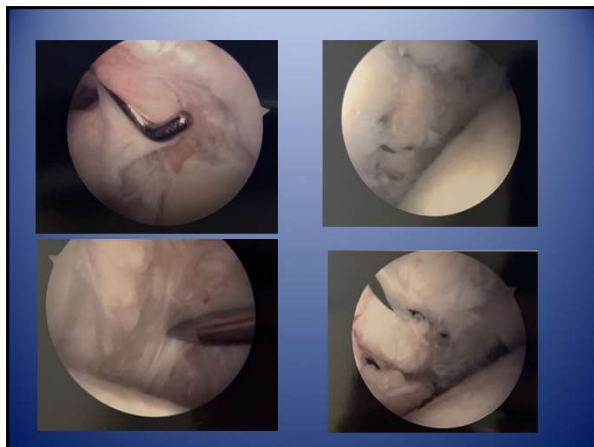
Shoulder Instability

- Non-op Treatment
 - Possible high risk of reoccurrence in young males
 - Immediate surgical intervention may be indicated
 - Therapy with understanding of risks an option
 - Therapy with focus on cuff strengthening and scapular proprioception
 - Corticosteroid maybe helpful to allow for more aggressive therapy

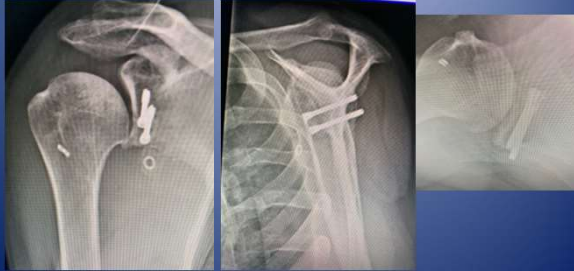Shoulder Instability

- Surgical Treatment
 - Dependent on if bone loss is present
 1. Arthroscopic primary repair
 2. Loss of bone (over 20% anterior glenoid)
 - Laterjet: coracoid transfer
 - Distal tibial allograft





Instability Treatment - Laterjet



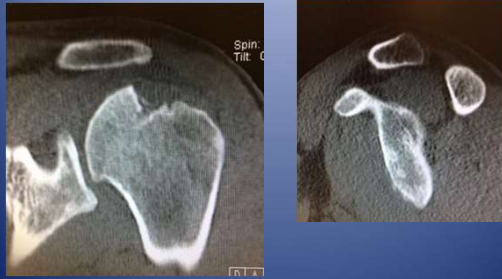Case - JB

- 30 yo active rock climber, skier, cross fit enthusiast
- 3 years ago developed left shoulder instability, 10 dislocations
 - Multiple ER visits required for reduction

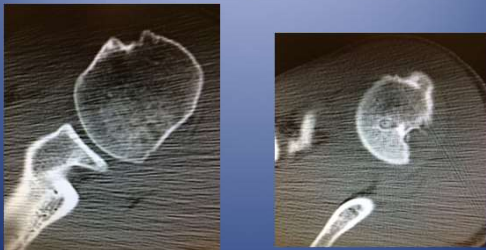Case - JB

- 30 yo active rock climber, skier, cross fit enthusiast
- 3 years ago developed left shoulder instability, 10 dislocations
 - Multiple ER visits required for reduction
- Underwent arthroscopic bankart repair with reimplassage by outside surgeon
 - 6 months after, redislocation with multiple reoccurrences

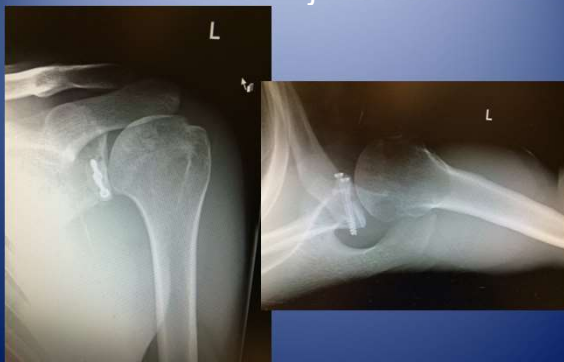JB



JB



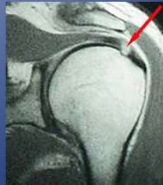Laterjet



Rotator Cuff Injuries

- Comprise the majority of shoulder complaints in patients over 50 years of age
- Account for approximately 2 million physician visits annually for rotator cuff problems

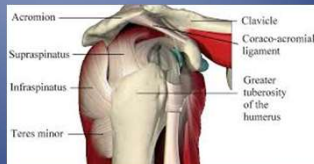Rotator cuff tear on an MRI



What is the rotator cuff?

- The rotator cuff consists of 4 muscles that originate on the scapula (shoulder blade) and attach to the humeral head (ball). These muscles are called:

- 1) *Supraspinatus*
- 2) *Infraspinatus*
- 3) *Teres minor*
- 4) *Subscapularis*

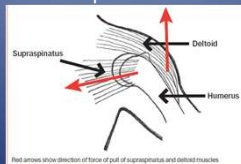


Shoulder anatomy (side view)

Rotator Cuff Function

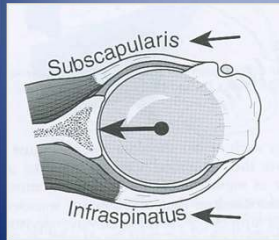
- The *supraspinatus*, *infraspinatus*, and *teres minor* function to:

- 1) rotate the forearm/hand away from the body (external rotation)
- 2) elevate the shoulder
- 3) balance the ball in the socket so the larger deltoid muscle can power shoulder motion



Red arrows show direction of force of pull of supraspinatus and deltoid muscles.

Rotator Cuff Function



The rotator cuff is important for normal shoulder function. It acts to:

- 1) Provide shoulder stability
- 2) Position the ball of the humerus in the socket
- 3) Actively move the shoulder

Rotator Cuff Disease and Injury

• Injury to rotator cuff tendons

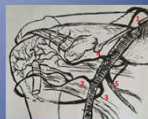- 1) Can occur from **trauma**
 - auto accident
 - fall
 - sporting injury
- 2) Can be damaged from **long standing wear and tear**
 - repetitive overhead activity and lifting
 - smoking
- 3) Or may be torn **without** any known specific reason
 - this may be a function of the patient's individual shoulder anatomy



Rotator Cuff Disease and Injury

• The native blood supply to the rotator cuff is generally limited

- Blood supply continues to diminish further with aging
- Smoking or diabetes will also cause diminished blood supply to the tendons



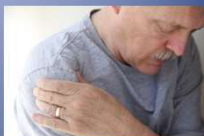- This limited blood supply reduces the ability of the tendon to heal itself when injured and places the tendon at risk for tearing

Rotator Cuff Disease and Injury

- Tears of the rotator cuff may either be full-thickness or partial-thickness tears
 - 1) A **full-thickness tear** means the tendon has been completely torn off of its insertion on the humerus (greater tuberosity)
 - 2) A **partial-thickness tear** means the tendon is still attached to the humerus, but some fibers of the tendon have torn
 - This can include tearing in the middle portion of the tendon (mid substance)
 - Or, can include partial tearing of the tendon at its insertion

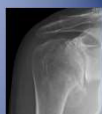Diagnosis

- Patients with rotator cuff tears commonly report the following symptoms:
 - Pain along the outside (lateral) aspect of the shoulder
 - Pain with overhead motion and activities
 - Pain that may wake someone up from sleeping
 - Fatigue with holding the arm overhead
- **Remember!** Check motion to rule out adhesive capsulitis



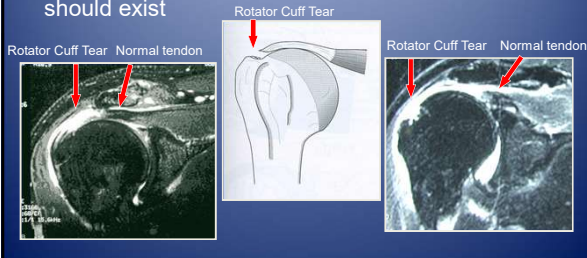
Diagnosis

- In patients with concern for rotator cuff tear, a physician will typically order:
 - X-rays: obtained in clinic
 - Help to rule out other diagnoses (such as arthritis)
 - Examine the position of the ball in the socket
 - MRI
 - Best tool to evaluate the soft tissue structures of the shoulder, notably the rotator cuff
 - Can typically delineate between partial and full thickness tears, tear size, quality of tissue



Magnetic Resonance Imaging (MRI)

- Allows visual evaluation of soft tissue structures
- Reliability of diagnosing full-thickness RCT: 89-98%
 - Consistently able to predict cuff tear size
- Tear appears as a white spot where black tendon should exist



Treatment

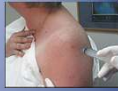- For patients with partial-thickness rotator cuff tears that do not occur from a single traumatic injury, *non surgical* treatment is typically the first line of treatment
 - Modalities:
 - 1) Activity modification
 - 2) Anti-inflammatory medicine
 - 3) Physical therapy
 - 4) Steroid injections



Physical Therapy

- Often, patients can benefit from 6-8 weeks of treatment with a licensed physical therapist
- Goals of therapy include:
 - 1) Regaining any lost shoulder range of motion
 - 2) Strengthening the injured rotator cuff muscle and the supporting cuff muscles
 - 3) Balancing the shoulder and shoulder blade to position the ball of the humerus in a more optimal place to allow for healing
 - 4) Strengthening/balancing of the rest of the body

Steroid Injections

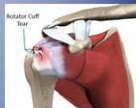

- Steroid injections may be considered in select patients to treat pain and inflammation
- Steroids are incredibly strong anti-inflammatory medications
- Using a needle, steroids are delivered directly to the area of inflammation without the risk of whole body side effects (systemic) that may occur if taken by mouth
- Too many steroid injections can actually injure the tendon over time

Acute Full-Thickness Rotator Cuff Tear

- Patients who have an injury and are found to have an **acute full-thickness** tear are often considered immediate surgical candidates
- Patients who sustain an acute full-thickness tear have been shown to have good-excellent outcomes when surgery is performed within 12 weeks of injury
 - Therefore, patients who injure their shoulder and have symptoms such as an inability to lift the arm should seek early evaluation by an orthopaedic surgeon

Chronic Full-Thickness Tear



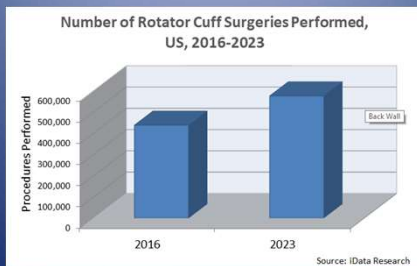
- Patients with chronic full thickness tears may have had no traumatic injury, but report shoulder pain or a decrease in function that increases over time
- Depending on age, activity, and size of the tear these patients may try non-surgical treatment initially
- For patients who continue to have symptoms, surgery can be indicated

Full-Thickness Rotator Cuff Tear

- What we don't know about full-thickness rotator cuff tears is how they change with time if they are not surgically repaired
- A major concern with full-thickness tears is if the tear will become larger and larger over time
 - With time, if the tear becomes too large or diseased, it may get to the point that it cannot be fixed
 - It is unclear at this time which patients are at risk for this

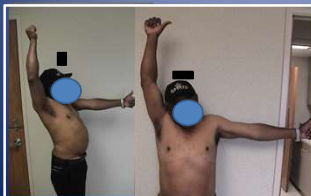Rotator Cuff Repair - Overview

- 2016: >460,000 RCR performed per year
(idataresearch.com)
 - Project this will be over 600,000 by 2023

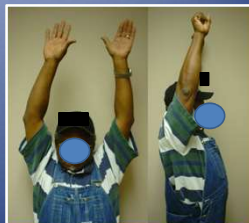

Rotator Cuff Repair – Ultimate Goal

Pre-Operative



Post-Operative



Arthroscopic Rotator Cuff Repair

- Most rotator cuff tears are able to be repaired using arthroscopic techniques
- Several small incisions are made around the shoulder, these are approximately 1 cm in length
- This allows for a camera to be placed into the shoulder. The surgeon can then visualize the inside of the shoulder and the rotator cuff on a television screen without making a large, invasive incision

Intraoperative Instruments

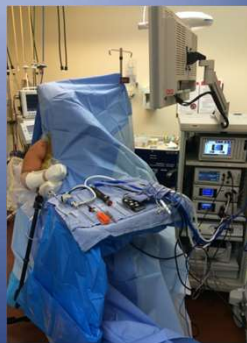- Specially designed instruments are placed into the shoulder through the portal incisions that allow for evaluation and manipulation of the structures of the shoulder
- Some commonly used instruments include:
 - Probe to palpate structures
 - Grasper to move and hold tissues, as well as grab suture
 - Suture passer to pass suture through the cuff tendon



Grasper/Retriever

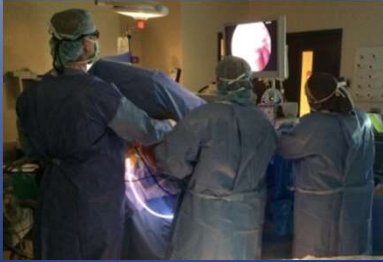Intraoperative Setup

- This is what the set up looks like after the patient has been positioned, the arthroscope has been set up and sterile drapes have been placed around the surgical site



Intraoperative Setup

- This is the setup during the actual procedure. The team is looking at the projection of the shoulder from the arthroscope on the TV monitor

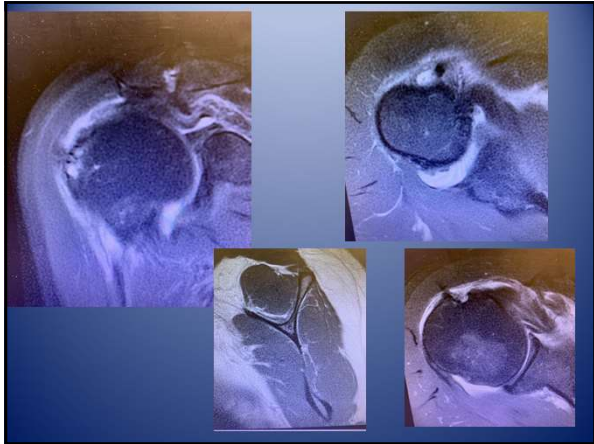


Case - SW

- 50 yo female
- Works at Chick-fil-A
- Tripped over a rug at home and fell onto her right shoulder
 - Unable to lift arm
 - No history of shoulder pain

SW

- Exam
 - Active elevation with 4/5 strength to 120
 - ER to 40 degrees with 4/5 strength, subtle lag sign
 - Weakness with belly press test



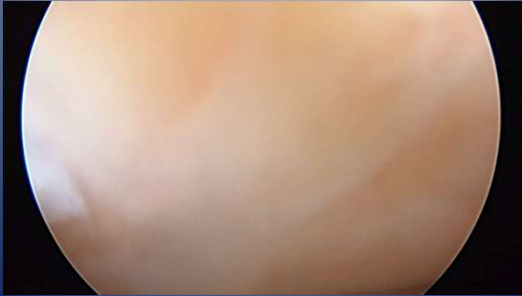SW

- Diagnosis
 - Acute rotator cuff tear
- Treatment
 - Surgical intervention (arthroscopic repair)

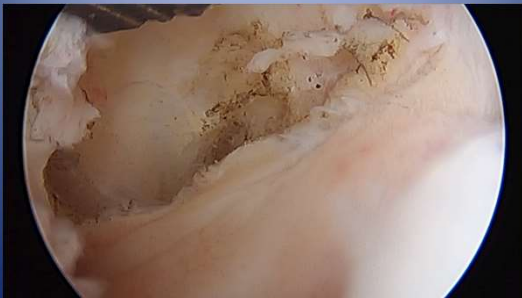SW - Arthroscopic Evaluation

An arthroscopic view of a shoulder joint. The image shows the internal structures of the joint, including the rotator cuff and the glenohumeral joint. A surgical instrument is visible, indicating an arthroscopic procedure.

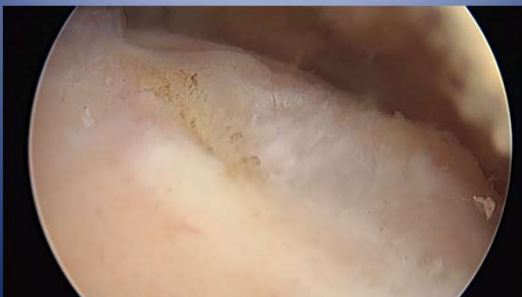SW – Biceps Tenodesis



SW – Subscapularis Repair



SW – Rotator Cuff Repair



RCR Duration of Recovery: *It's Long!*

- Kim et al., CORR 2019
 - 2 year prospective study 135 ARCR patients
 - Average recovery time
 - High level ROM (behind back IR) – 9 months
 - Simple strength activities – 10 months
 - Full sports/leisure activities – 14 months
 - Large/massive tears – all return to activities delayed
 - 20% overall re-tear rate

Risk of repair failure

- Repair failure after RCR exists!
 - Rates 11-94% reported in literature:
 - Partial tears/small full thickness: 5-10%
 - Moderate tears: 20%
 - Large tears: 25%
 - Massive Tears: 40-50%
- Kim et al., 2014 JBJS
 - Cuff re-tear negatively affect clinical outcome including ASES, SST, and function

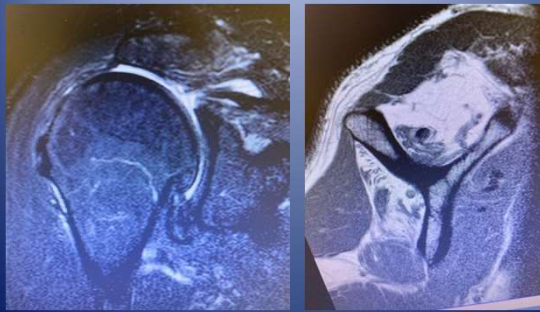
What is the incidence of postoperative stiffness?

- Hubertly et al., Arthroscopy 2009
 - Incidence and treatment for postoperative stiffness after ARCR
 - 489 patients
 - 24 patients developed stiffness that required surgical treatment (**4.9%**)
 - 100% rate satisfaction after capsular release
- Denard et al., Arthroscopy 2011
 - Systemic review (7 articles) post ARCR stiffness
 - Incident of transient stiffness: 10%
 - Rate of post-adhesive capsulitis requiring surgical release: **3.3%**

Summary

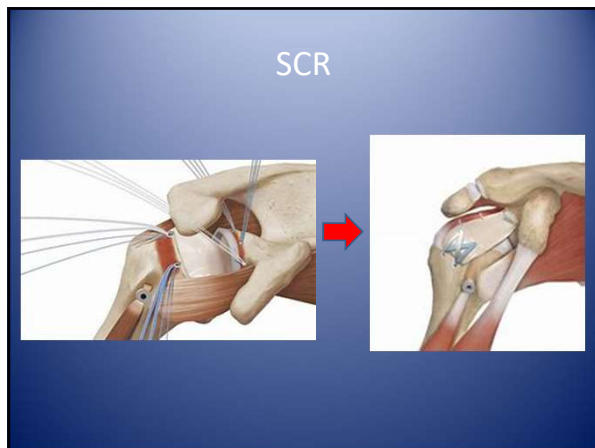
- Early/more aggressive postoperative rehab protocol
 - May improve early pain relief and motion
 - Do not appear to improve outcomes at the 1 year mark
- Most cuff failures likely occur within 3 months postop
 - Early postoperative stiffness maybe associated with cuff repair integrity
- Incidence of surgical management for postoperative adhesive capsulitis following ARCR only 3.3-4.9%

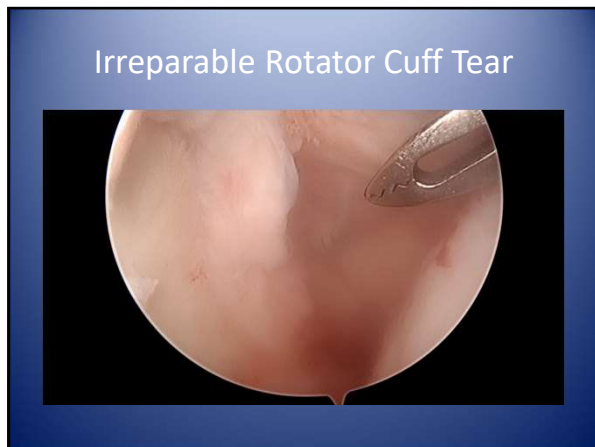Newer Techniques – Irreparable RCT

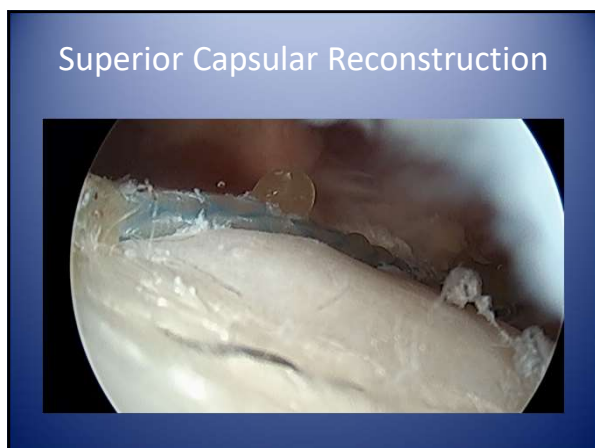

Newer Techniques – Irreparable RCT

- Superior Capsular Reconstruction
 - For irreparable posterior superior rotator cuff tears
 - Dermal allograft patch is used to reconstruct the superior capsular ligament
 - This holds the humerus depressed in the socket
 - Can improve elevation function and provide pain relief
 - Good for young active patients with pain but not pseudoparalytic







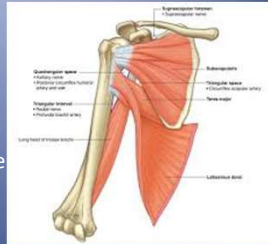
Newer Techniques – Irreparable RCT

- **Latissimus Transfer**

- For irreparable subscapularis rotator cuff tears

- Transfer latissimus to lesser tuberosity

- Prevents anterior translation of humeral head



Case - RS

- 61 yo rancher from west Kansas
- Run over by a cow sustaining a left shoulder isolated subscapularis full thickness tear
- Underwent open subscapularis repair with a two row technique and biceps tenodesis by an outside surgeon

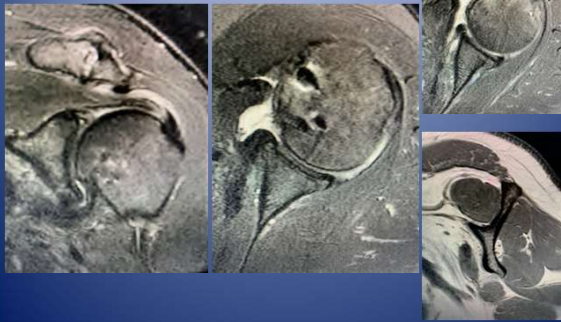RS

- 7 weeks postop the patient fell over a grain auger with an increase in pain and weakness
 - Referred to my practice
- Clinical findings consistent with subscapularis dysfunction?

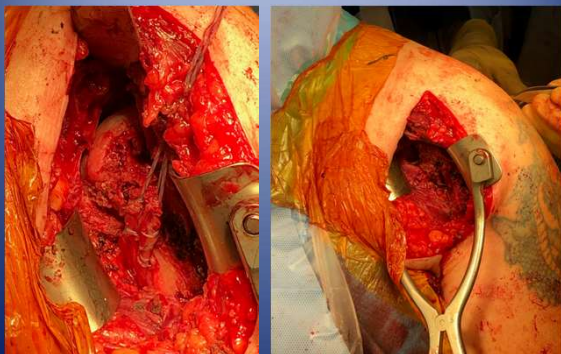
RS

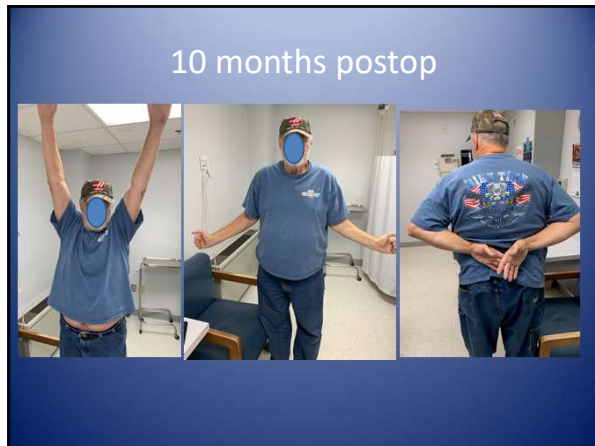- 7 weeks postop the patient fell over a grain auger with an increase in pain and weakness
 - Referred to my practice
- Clinical findings consistent with subscapularis dysfunction?
 - Clinical exam:
 - + belly press test
 - + lift off test
 - Pain and weakness with resisted elevation

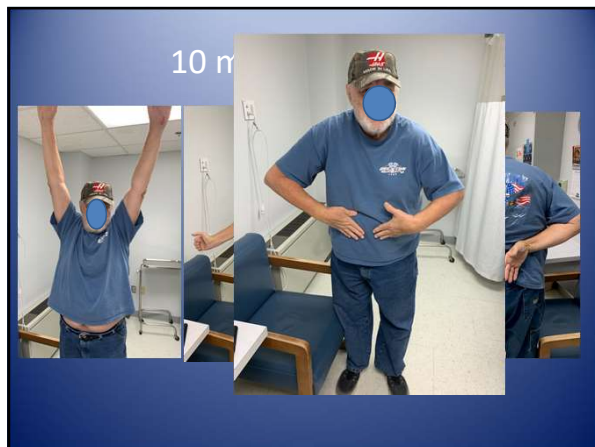RS



RS – Latissimus Transfer





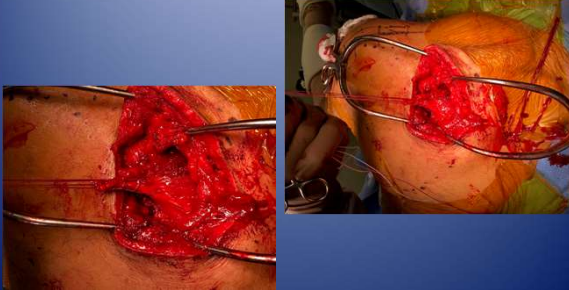


Newer Techniques – Irreparable RCT

- **Lower Trapezius Transfer**
 - For irreparable posterior superior rotator cuff tears
 - Transfer lower trap to greater tuberosity with allograft
 - Provides dynamic potential to head
 - External rotation

Case - MS

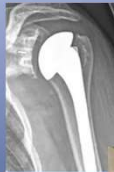- Lower trapezius transfer



Shoulder Replacement

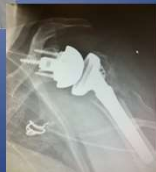- **Anatomic TSA**

- Intact rotator cuff



- **Reverse TSA**

- Nonfunctional rotator cuff



Shoulder Replacement

- **Total shoulder arthroplasty**

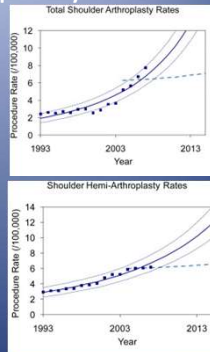
- Over 90,000 surgeries performed annually
 - doubles in frequency approximately every 7 years

- Outcomes

- 92-95% of patients: associated with pain relief, improved function, and patient satisfaction
- Implant survivorship is estimated >85% at minimum follow-up of 15 years

Shoulder Arthroplasty - USA

- Day et al., JSES 2010
 - TSA growth rates from 1993-2013
 - Comparable to THA/TKA
- Increase in TSA
 - 192% to 322% (2015)



Shoulder Arthroplasty – USA

- Westermann et al., Iowa Orthop J 2015
 - 2011 - 66,485 patients underwent shoulder arthroplasty
 - 29,359 TSA
 - 21,692 reverse TSA (RTSA)
 - 15,434 hemiarthroplasty (HA)

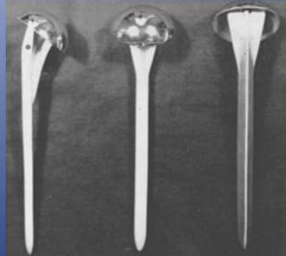
Historical Review



- First TSA – Pénan
 - 1893
 - Platinum and rubber
 - Single patient with TB arthritis
 - Removed after 2 years for extensive reactive process

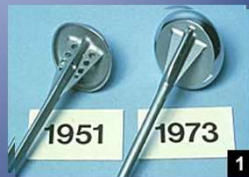1953 - Neer

- Vitallium prosthesis
 - Fracture/osteonecrosis
 - Initially 3 sizes



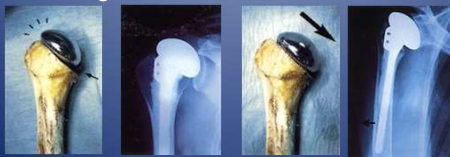Neer II - 1973

- Single piece – nonmodular
 - 5 sizes
- Increased sphericity
 - Improved fulcrum
- Cobalt chrome
- 2 head thickness (15 and 22 mm)
 - Based on 50 mm (1 inch) radius of curvature
 - 50° inclination
- Beginning of transition to attempt to replicate normal anatomy



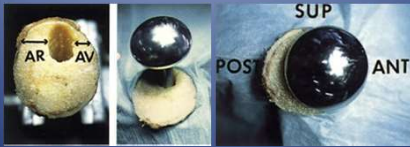Historical – no medial offset

- Insertion along metaphyseal axis
 - Inadequate plane orientation
- Requires tilt to reestablish articular surface
 - Length of stem – abutment with diaphyseal change in curvature



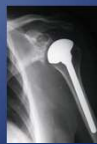Historical – no posterior offset

- Uncovered posterior aspect of cut
- May require resection of neck and artificial increase of humeral retroversion



1990's to current

- Modern concepts
 - Improved understanding of GH joint kinematics and anatomic relationships
 - Incorporation of modularity and adaptability to replicate variability in normal anatomy



Modern Head-Stem Design

- Modularity/Adaptability
 - replicates variability in normal anatomy



New Technology:
Stemless Humeral Design

- Standard stemmed implant

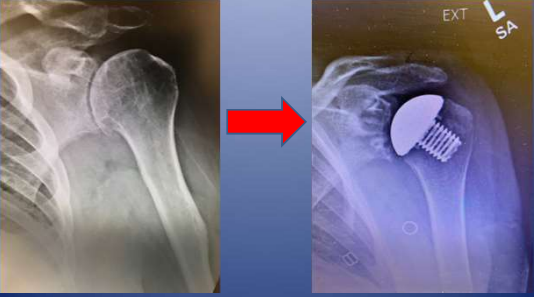


Stemless Humeral Design

- IDE – Arthrex Eclipse



Eclipse Case – 64 yo male

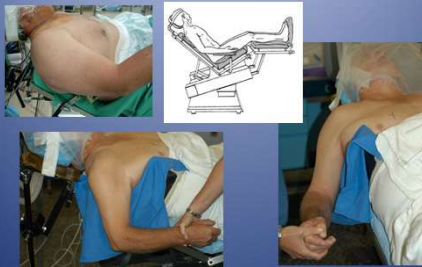


Glenoid Component

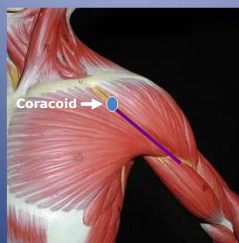
- Resurface arthritic glenoid face
- Distribute applied load from humerus uniformly to adjacent bone
- Provide concavity to stabilize glenohumeral joint



TSA - Patient Positioning

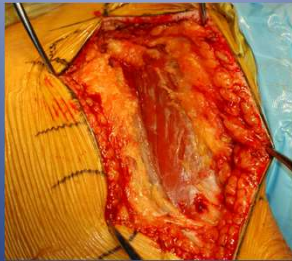


Surgery - Deltopectoral Approach



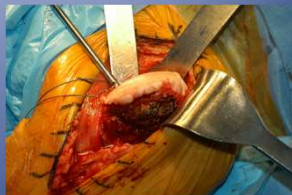Deltopectoral Approach

- Identify cephalic vein



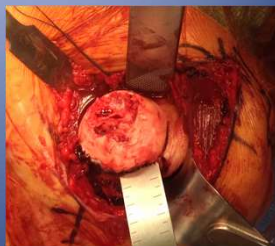Deltopectoral Approach

- Tenodesis BT long head
- Preserve cuff
- Dislocate proximal humerus

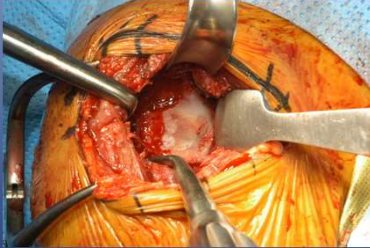

Humeral Head Excision

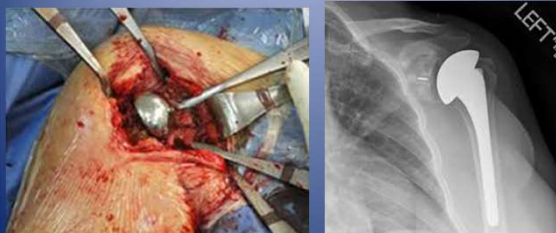
- Free hand cut with oscillating saw
- From here gain access to humeral canal
 - Placement of humeral implant



Glenoid Visualization

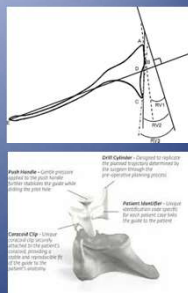


TSA Final Implants

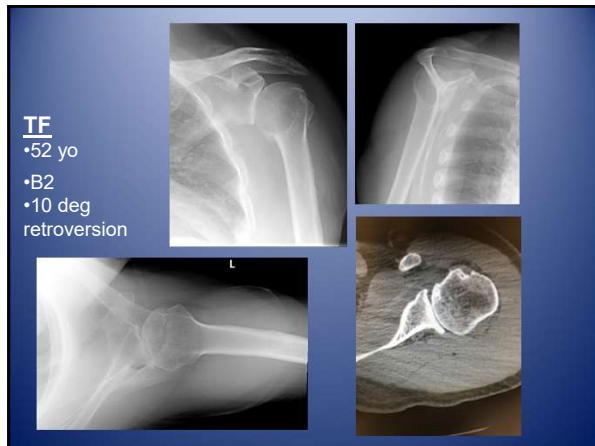


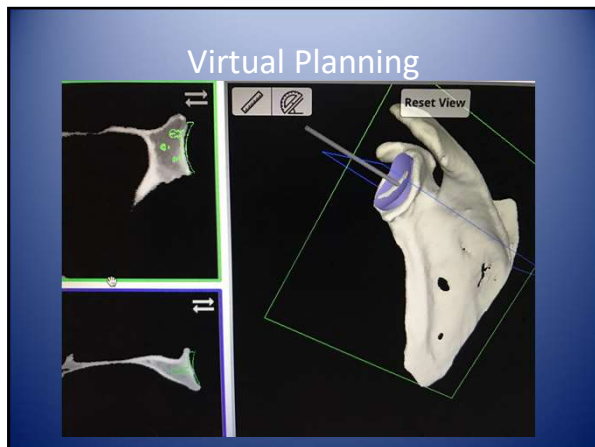
New Technology: Patient Specific Instrumentation

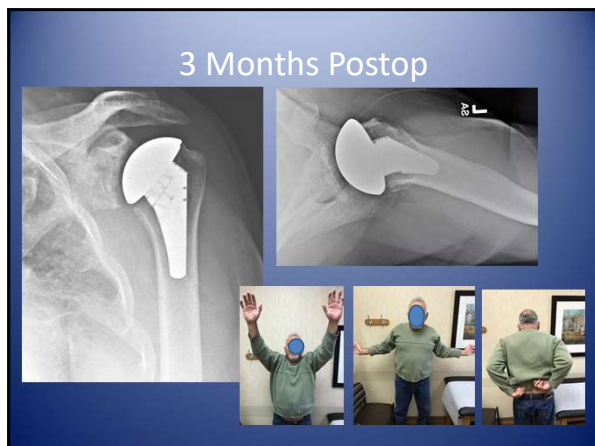- **Patient specific planning**
 - Virtual planning of glenoid (socket) position
 - Preoperative CT scan
 - Patient specific guide created for pin placement



Improve version correction, seating of implant





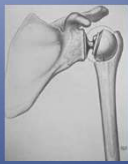

Virtual Planning

- Iannotti et al., 2015 JBJS
 - 46 TSA patients, virtually planned or not
 - Postop CT
 - Virtual planning significant improved glenoid position in version and inclination
- Hendel et al., 2012 JBJS
 - PSI with patient specific instrumentation improved:
 - preoperative understanding of glenoid pathology
 - selection of optimal implant
 - accuracy of implanted prosthesis

Reverse Total Shoulder Arthroplasty

- Reversal of the ball and socket components of shoulder arthroplasty

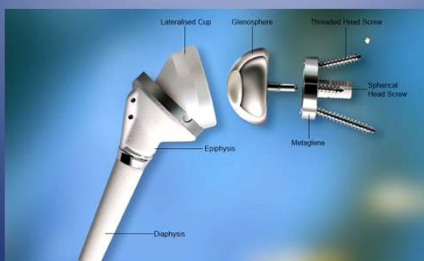

1985



Paul-Marie Grammont (1940-2013)

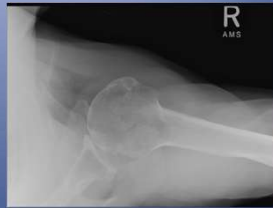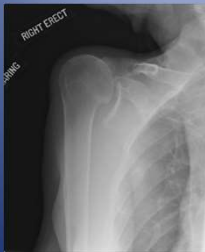Reverse Total Shoulder Arthroplasty



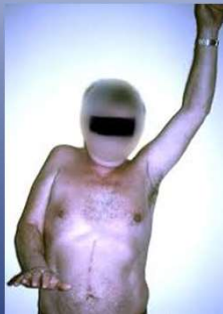Reverse Shoulder Arthroplasty

- Indications: expanding
 - Designed for >70 yo, end stage DJD with non functional rotator cuff
- Current
 - Irreparable RCT (no DJD)
 - Older patient with large massive acute RCT
 - Younger patient as salvage procedure
 - Majority revision arthroplasty cases
 - Bone loss around proximal humerus, glenoid
 - Osteolysis
 - Infection
 - B2 glenoid primary arthritis

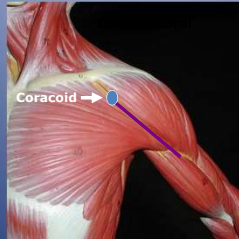
Typical patient: 72 yo s/p rotator cuff “repair”



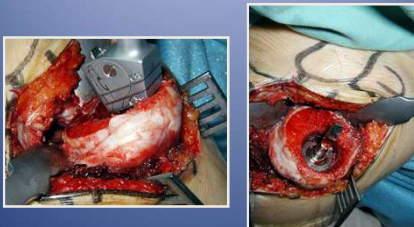
Pseudoparalysis



Surgical Approach



Humeral Preparation



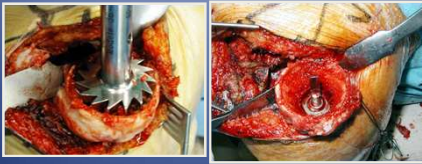Humeral Preparation

- Metaphyseal reaming

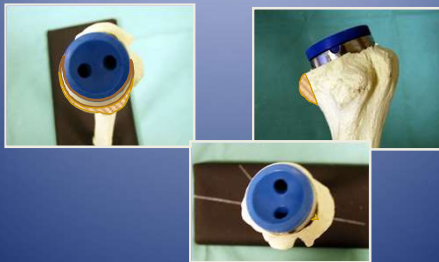

Humeral Preparation

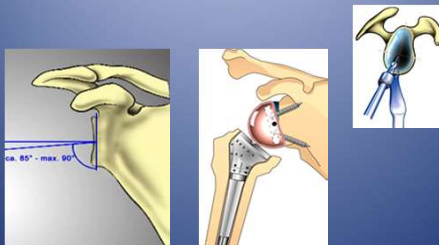- Metaphyseal reaming



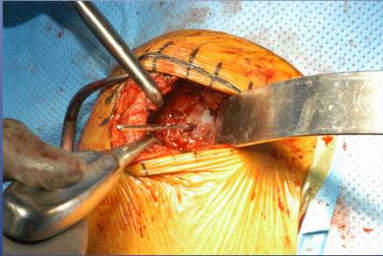Humeral Preparation



Glenoid Preparation



Glenoid Preparation



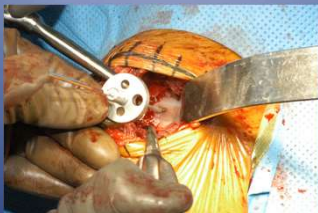Glenoid Preparation

- Ream for metaglen



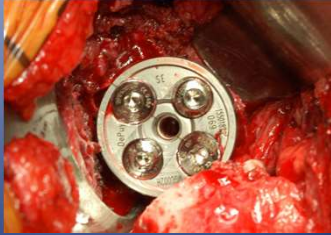
Glenoid Preparation

- Place guide pin

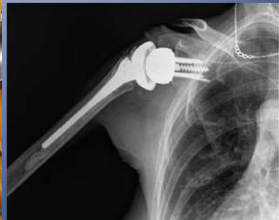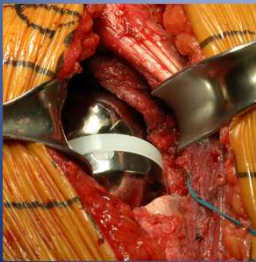


Metaglen

- Final implant

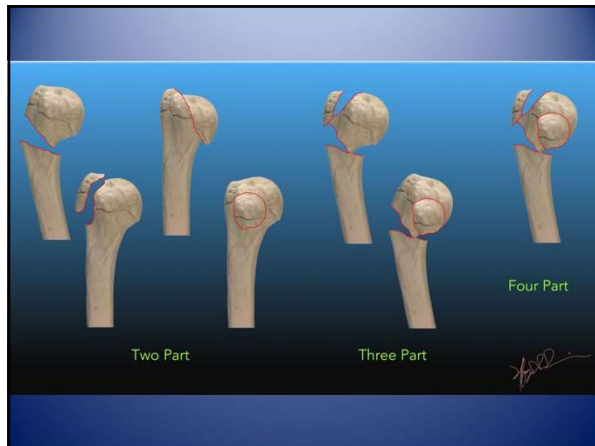


Final Reduction



Proximal Humerus Fractures

- Projected to account for 275,000 ED visits by 2030.
- Neer Criteria for determining fracture type
 - Based on number of fracture fragments
 - 2 part: surgical neck fracture (or isolated GT)
 - 3 part: surgical neck fracture with GT fracture
 - 4 part: surgical neck fracture with GT and LT fracture

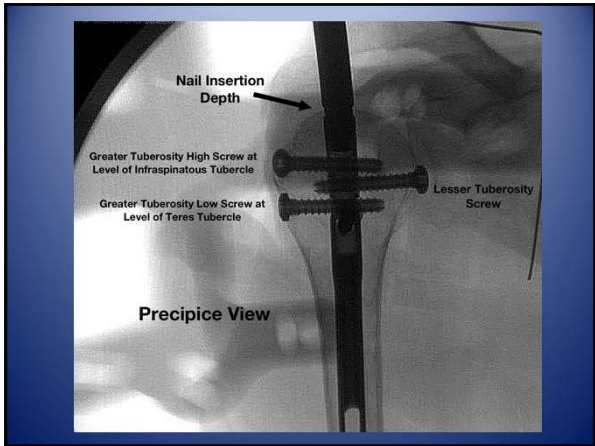


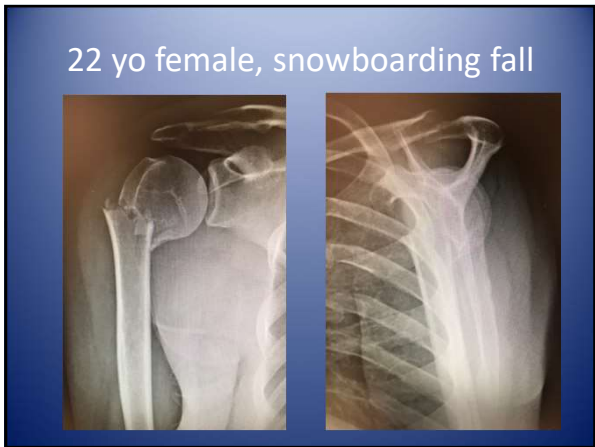
Proximal Humerus Fractures

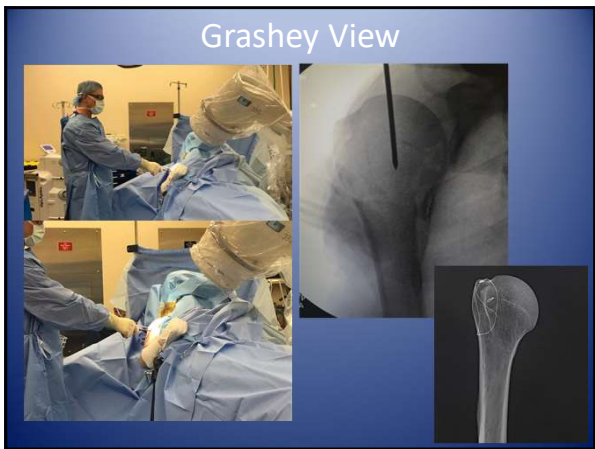- Most fractures can be treated nonoperatively
- Most can be considered fractures of fragility
- Some displaced fractures may be better treated with surgery
 - Still unclear which patient

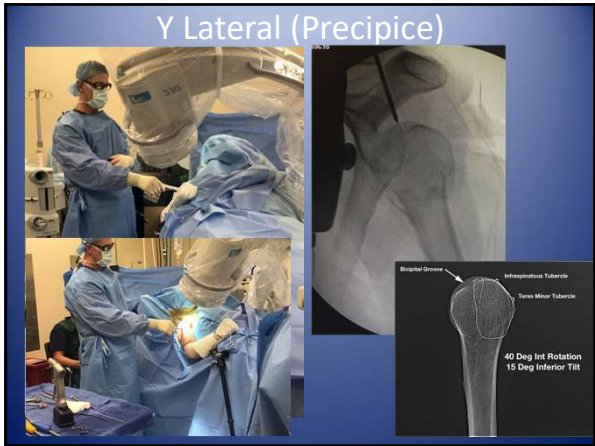
Proximal Humerus Fractures

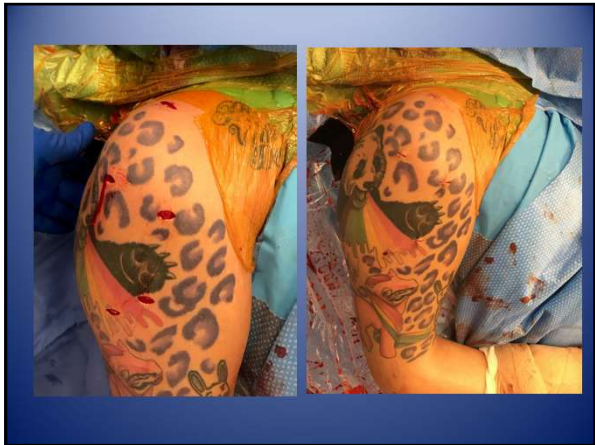- What's new with surgical management ?
 1. Maybe we are over treating
 - PROPER randomized trial: JAMA 2015
 - No difference at 2 years surgery vs non-op
 - Authors selected out surgical candidates prior to inclusion
 - Currently unclear who needs surgery
 2. Treatment of fracture with intramedullary fixation
 - Plate fixation gold standard
 - IMN offers biomechanical and vascular benefits

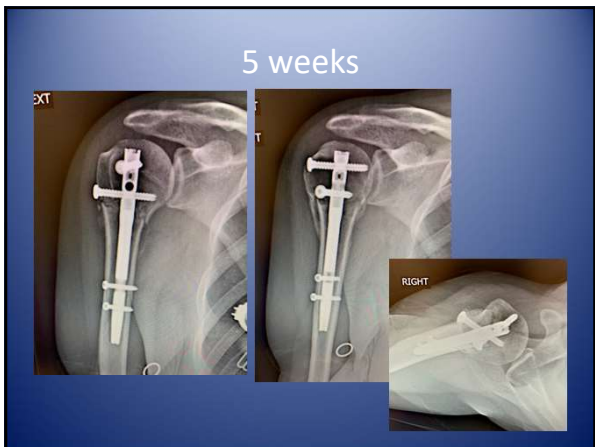


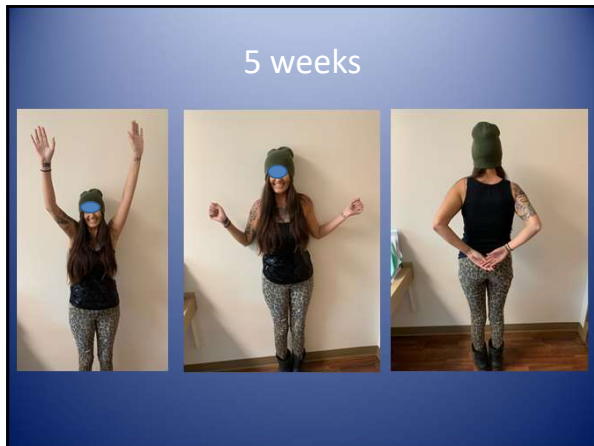


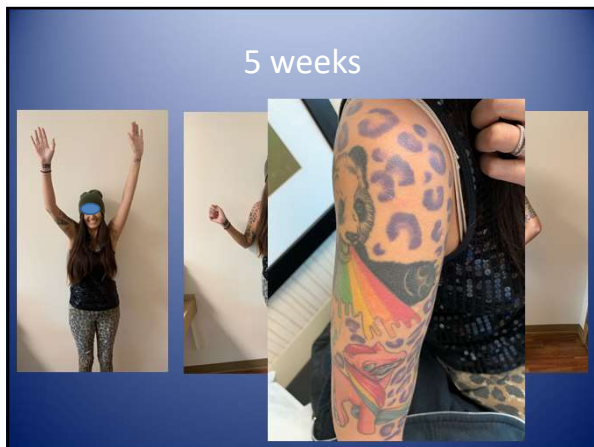

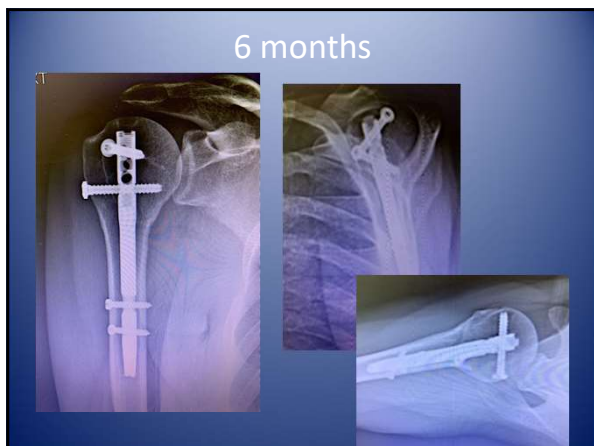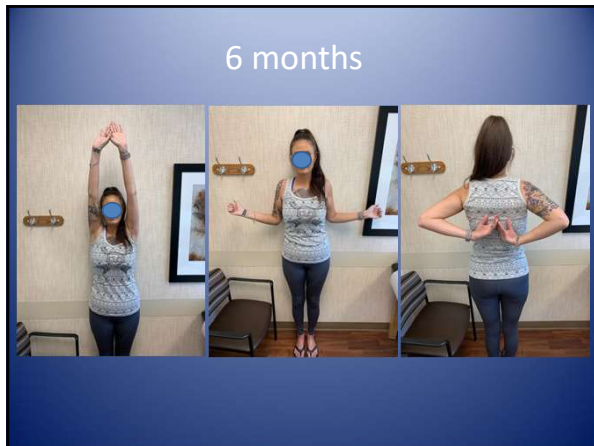


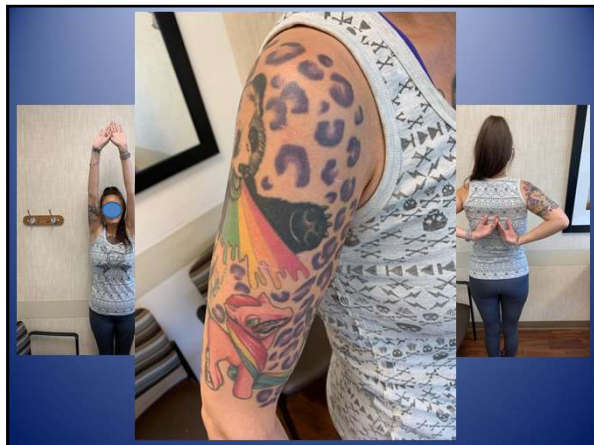


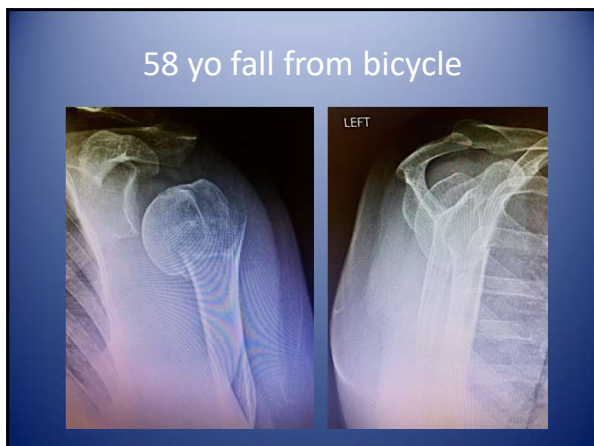




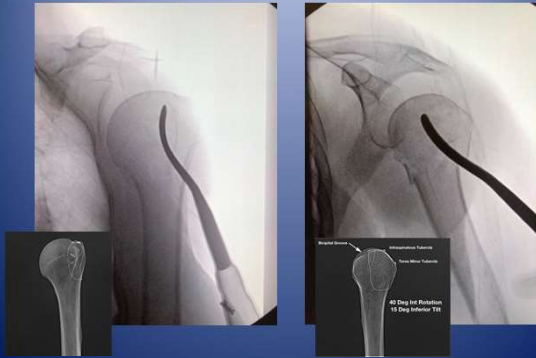




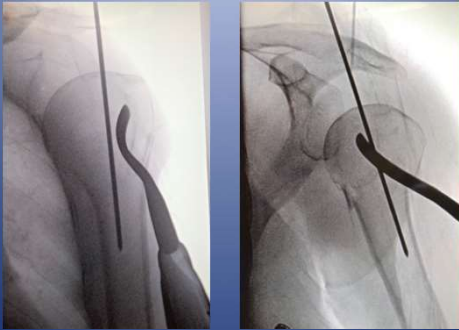


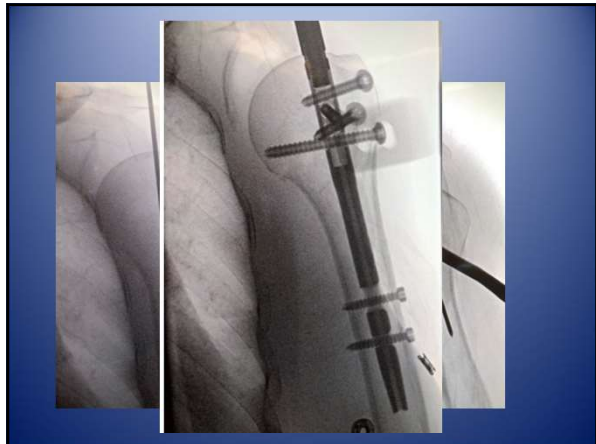


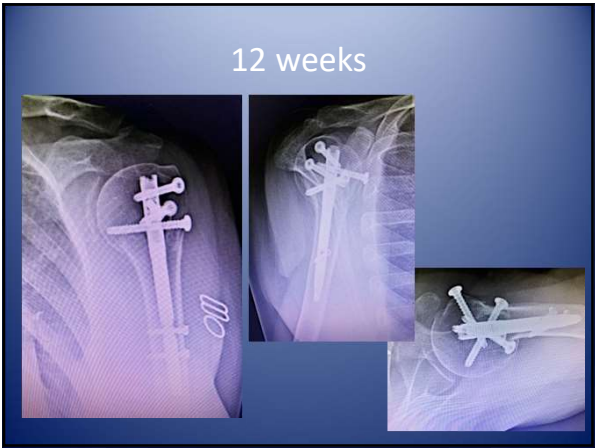Reduction

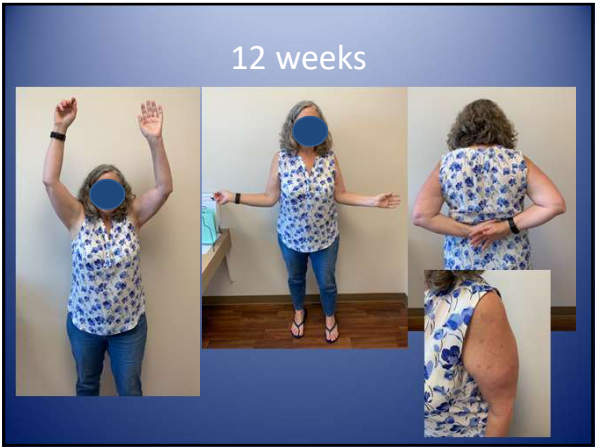

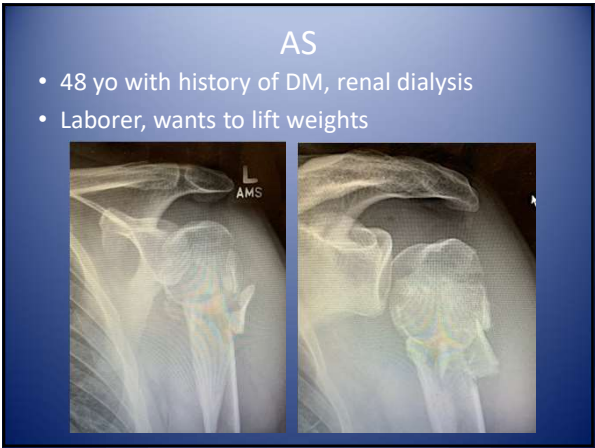
Starting Point

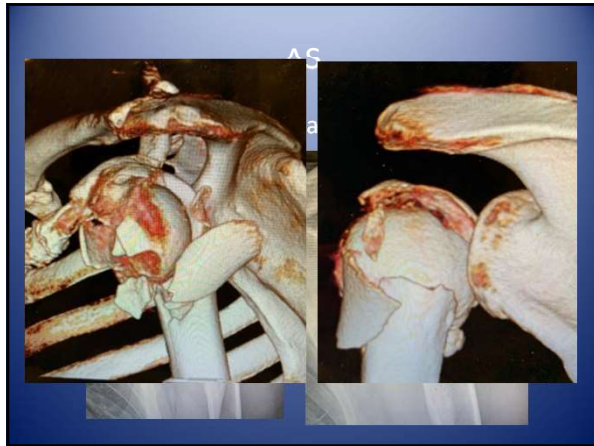

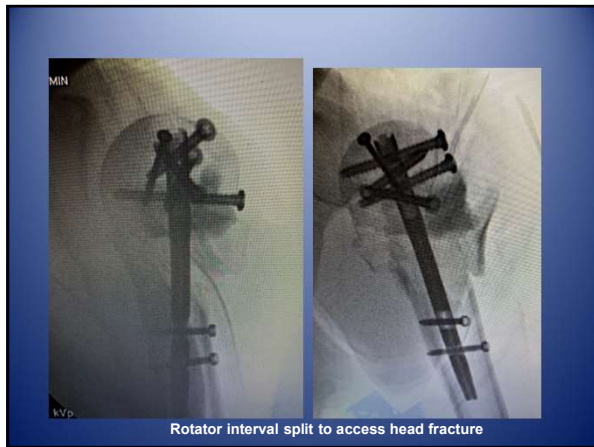


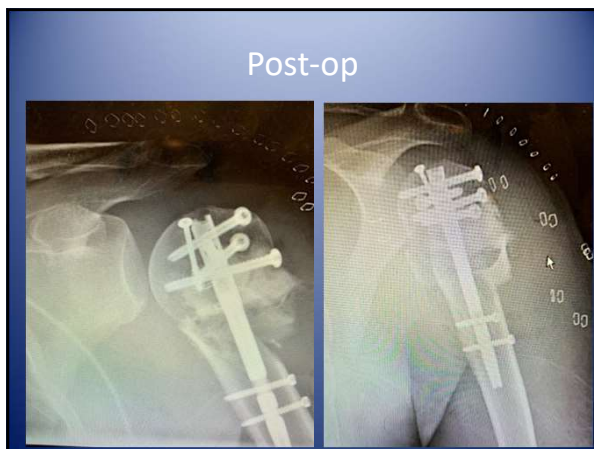



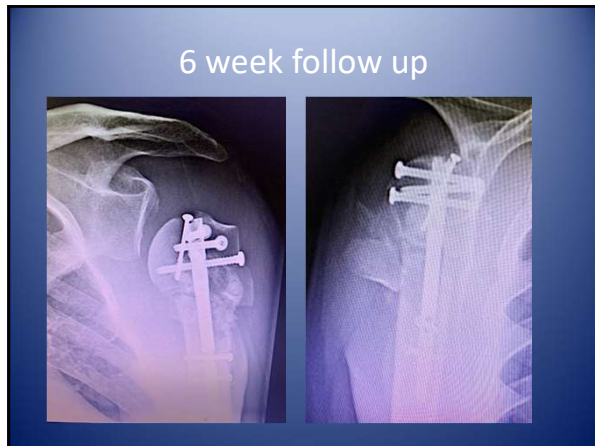


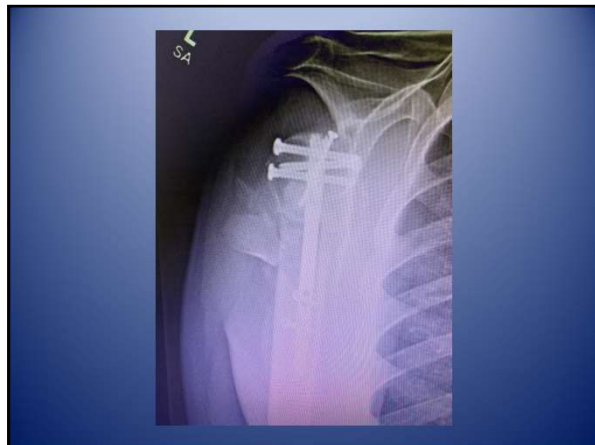









Western - Patient Outcomes

- **61 patients:** > 1 year follow up
 - SANE: avg. 83.3
 - 2 part (n=26): 86.1
 - 3 part (n=21): 77.7
 - 4 part (n=14): 87.4
 - Avg. ROM (all patients)
 - Flexion: 132
 - Abduction: 133
 - ER: 52
 - Complications
 - AVN: 4 patients (6.5%)
 - Underwent capsular release: 6 patients (9.8%)
 - Conversion to reverse TSA: 3 patients (4.9%)

What's New In Shoulder Care

- Lots of things!
- Indications and technology changing all the time
- Management of rotator cuff disease consistently adapting and improving
- Shoulder arthroplasty technology changing every 2-3 years
- Future is exciting

Thank You!

Ben Sears, MD

searsbw@gmail.com

denvershoulderandelbow.com

